

# Tubularized Incised Plate Urethroplasty for Primary Hypospadias Repair: Versatility versus Limitations

**Original Article** *Amr A. AbouZeid*

*Department of Pediatric Surgery, Faculty of Medicine, Ain-Shams University, Cairo and Benha Children Hospital, Benha, Egypt*

---

## ABSTRACT

**Introduction:** Several techniques have been described for the repair of hypospadias but without any definitive privilege of one technique over the others. The choice of the repair remains largely dependent on the judgment and personal experience of the operating surgeon.

**Aim of Study:** The aim of this study was to identify the most commonly encountered complications following tubularized incised plate (TIP) urethroplasty and their rate of occurrence in relation to different forms of hypospadias.

**Patients and Methods:** This study was conducted on patients with different degrees of hypospadias (ranging from distal penile to scrotal hypospadias) who underwent primary TIP urethroplasty. All included cases were operated by the same surgeon (the author) at two tertiary centers for pediatric surgery during the period 2007 through 2016. Data analysis was performed in a retrospective manner based on retrieved medical records, in addition to saved digital photography documenting the preoperative phenotypic severity of the hypospadiac phallus, operative steps, appearance at follow-up visits, postoperative investigations, and reoperations.

**Results:** We retrieved data of 193 patients with different degrees of hypospadias who underwent a primary TIP urethroplasty during the 10-year period of the study. All cases in the study completed their early postoperative follow-up (at 1 and 4 weeks). Approximately 40% of cases completed more than 1-year follow-up (mean: 2.3 years, median: 2 years). Rate of reoperation was 21.7% (20 cases for fistula, five recurrences of chordee, one meatal stenosis, and 16 skin refashioning and correction of penoscrotal interposition). All cases who returned for reoperation underwent urethral calibration under anesthesia±cystoscopy.

**Conclusion:** TIP urethroplasty is a versatile technique that can be used for the repair of different degrees of hypospadias with low rate of complications. The main limitation is the presence of considerable chordee (moderate or severe) when urethral plate preservation and dorsal penile plication might be a suboptimal way of management that is liable for recurrence of the ventral curvature.

**Key Words:** Chordee, outcome, proximal hypospadias, tubularized incised plate.

**Received:** 13 November 2017, **Accepted:** 10 January 2018

**Corresponding Author:** Amr A. AbouZeid, MD, Department of Pediatric Surgery, Faculty of Medicine, AinShams University, **Tel.:** +20 111 656 0566, **E-mail:** amrabdelhamid@hotmail.com.

**ISSN:** 2537-0014

## INTRODUCTION

Surgical repair of hypospadias is a frequently discussed topic in pediatric urology<sup>[1]</sup>. Several techniques have been described for the repair of hypospadias, but without any definitive privilege of one technique over the others<sup>[2]</sup>. The choice of the repair remains largely dependent on the judgment and personal experience of the operating surgeon<sup>[3]</sup>.

In 1994, Snodgrass made a breakthrough by introducing the 'TIP' procedure (TIP urethroplasty)<sup>[2, 4]</sup>. At first, the technique was used for the repair of distal hypospadias, but later, its use has been extended to proximal forms as well<sup>[5]</sup>. The technique has rapidly gained widespread

acceptance owing to its simplicity, reproducibility, low rate of complications, and better cosmetic results<sup>[3, 6]</sup>. Recent surveys have shown the TIP procedure to be universally the most frequent technique used for the repair of distal hypospadias (ranging from 59% up to 92%)<sup>[7-9]</sup>. However, its use in proximal hypospadias did not exceed 16% in most surveys<sup>[8,9]</sup>; the main obstacle being the presence of ventral penile curvature (chordee)<sup>[6,7]</sup>.

In this report, we tried to present the analysis of a carefully recorded 10-year experience of a single surgeon with a single technique (TIP urethroplasty) used for the primary repair of different degrees of hypospadias. Our aim was to identify the most commonly encountered complications following the TIP procedure and their

rate of occurrence in relation to the different degrees of hypospadias; this would help to clarify indications and contraindications for such a common procedure.

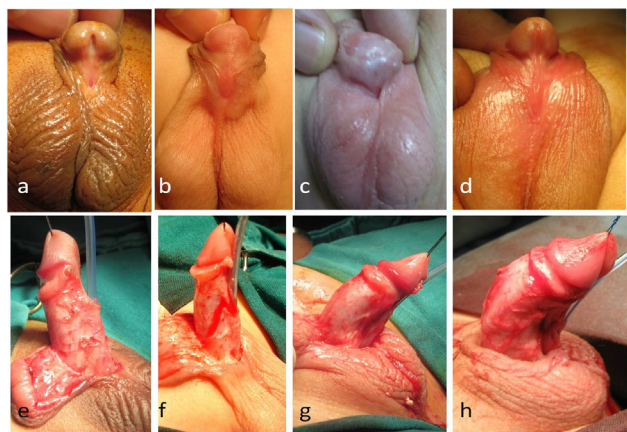
**PATEINTS AND METHODS**

This study was conducted on patients with different degrees of hypospadias (ranging from distal penile to scrotal hypospadias) who underwent primary TIP urethroplasty. All included cases were operated by the same surgeon (the author) at two tertiary centers for pediatric surgery during the period 2007 through 2016. We excluded ‘minor’ glanular forms (usually managed by a ‘MAGPI’ procedure) and those with severe chordee who required transection of their urethral plate. The study was conducted after internal review board approval.

Data analysis was performed in a retrospective manner based on retrieved medical records that included preoperative examination sheets, operative details, and follow-up notes, in addition to saved digital photography that included photographs documenting the preoperative phenotypic severity of the hypospadiac phallus, operative steps, appearance at follow-up visits, postoperative investigations (cystoscopy and urethrograms), and reoperations.

**Surgical technique**

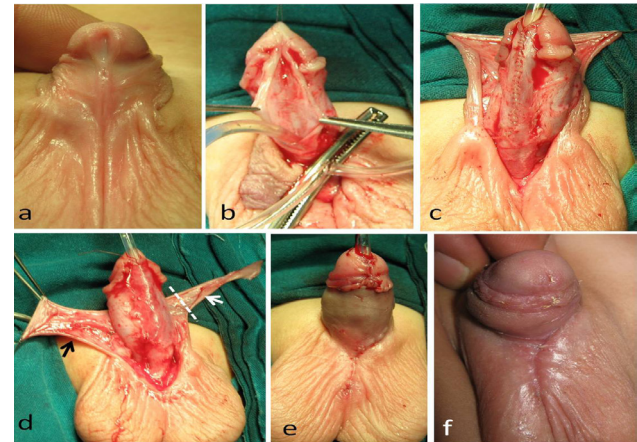
We start by degloving of the penile skin. A circumferential subcoronal incision is made around the glans starting on the penile dorsum to stop at the level of the urethral plate on both sides. A U-shaped incision is made ventrally around the urethral plate and the meatus. Then, we complete degloving of the penile skin taking down all the ventral attachments to the urethral plate and corpus spongiosum to release any bands that may contribute to the ventral curvature or penile rotation (Fig. 1).



**Fig. 1:** Different cases of hypospadias with variable phenotypic severity (a–d), and their corresponding intraoperative appearance (e–h). Note the variable degrees of ventral penile curvature (lower row) that became disclosed after penile degloving.

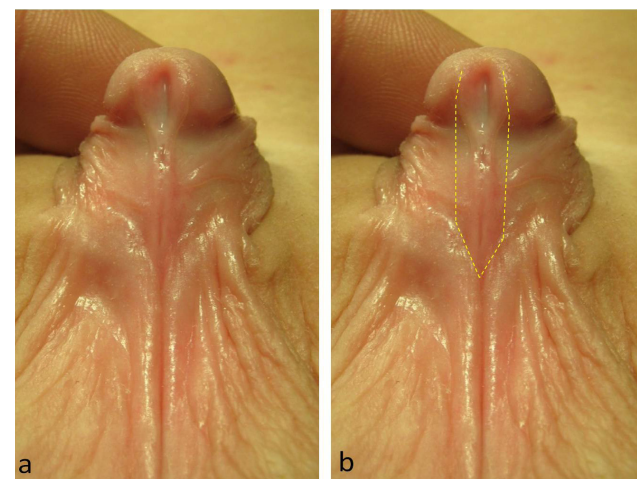
After completion of this step, one must decide whether it will be possible to preserve the urethral plate to proceed with a TIP procedure<sup>[3]</sup>.

We have never found a narrow urethral plate to be an obstacle for performing a primary TIP urethroplasty. A narrow plate is usually compensated by being thicker, allowing for a deeper midline incision to produce considerable increase in its width (Fig. 2).



**Fig. 2:** Steps of tubularized incised plate urethroplasty in a 12-month-old boy with penoscrotal hypospadias. (a) Preoperative appearance. (b) Midline incision of the urethral plate. (c) Tubularization of the incised plate. (d) Splitting the dorsal prepuce into two halves (Byars flaps), with each serving a function: the subcutaneous dartos layer is dissected from the left half (white arrow) and utilized for covering the urethroplasty, while the skin of doubtful viability is excised (dashed line); the right half (black arrow) is spared to reconstruct deficient ventral penile skin. (e) After skin closure. (f) Follow-up after 2 weeks.

However, what we have learned in such situation is to go more laterally with the two limbs of the U-shaped incision over the ventral penile skin to avoid separation of the urethral plate from the shaft when incised (Fig. 3).



**Fig. 3:** (a) A case of penoscrotal hypospadias with a narrow urethral plate (same case in Fig. 2). (b) The dashed line is marking for the U-shaped incision of tubularized incised plate urethroplasty.

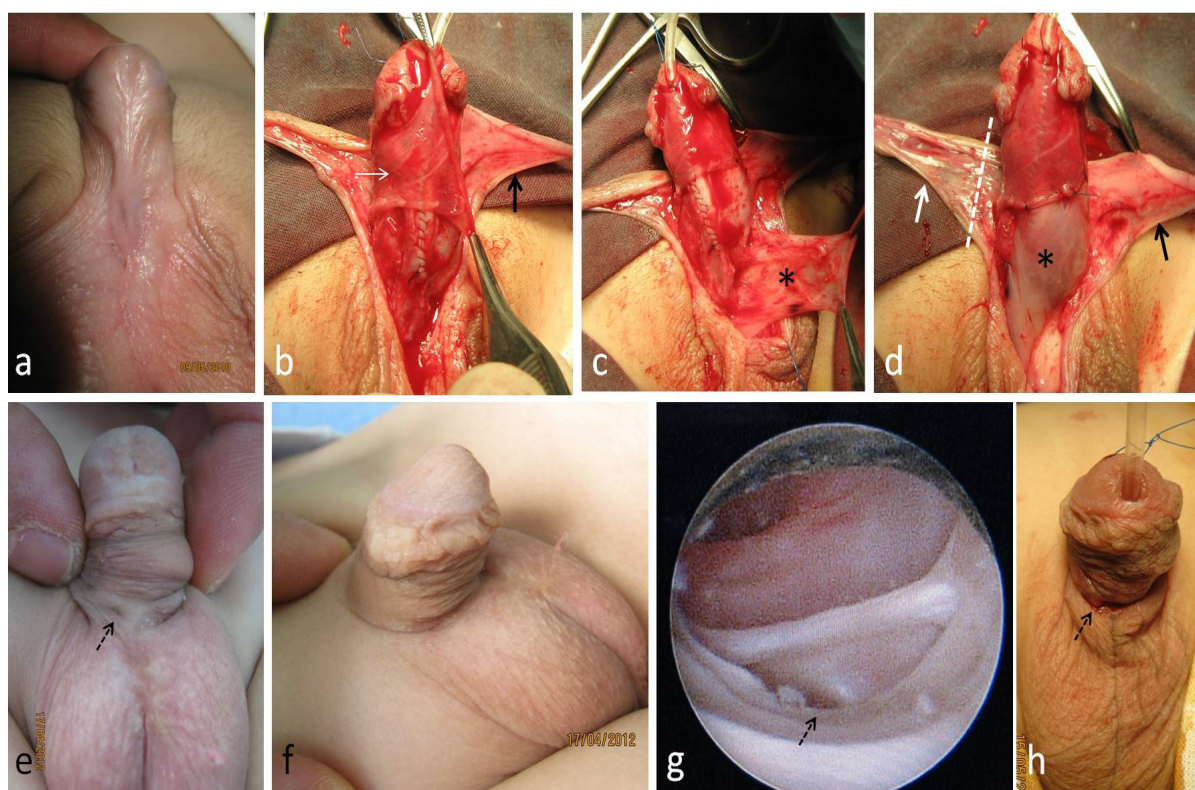
In these circumstances, the ventral penile skin on both sides of the urethral plate is usually fine and non-hair bearing to be safely included in the urethroplasty<sup>[7]</sup>. On the contrary, we have found the real obstacle for a TIP urethroplasty to be the presence of ventral penile curvature (Fig. 1).

The erection test is necessary to determine the degree of chordee, and the point of maximum curvature for proper placement of dorsal plication sutures (when indicated). Applying a ‘rubber band’ tourniquet at the base of the penile shaft can facilitate performing the erection test, and later, can decrease bleeding during dissection of the glanular wings. However, sometimes it is difficult to apply the tourniquet because of the very proximal location of the meatus (scrotal or penoscrotal). During the first 5 years of the study period, we used to manage moderate chordee ( $\leq 60^\circ$ ) by dorsal plication of the tunica albuginea (either midline or Nesbit), and go on with a TIP urethroplasty. However, because of having cases with recurrent chordee and for fear of exaggeration of chordee as the child goes into puberty<sup>[3, 7, 10]</sup>, we changed our practice; only mild chordee ( $< 30^\circ$ ) became amenable for urethral plate preservation and a TIP urethroplasty.

Adequate midline incision of the urethral plate is an essential step for a successful TIP urethroplasty, not only for increasing the width of the plate, but also for offering extra mobility for the two halves of the plate such that they can be easily rotated to be closed in the midline without

tension (hinging of the plate). Tubularization of the incised plate then starts opposite the mid-glans and proceeds in a proximal direction with continuous, full-thickness, single-layer (6-0) polyglactin suturing.

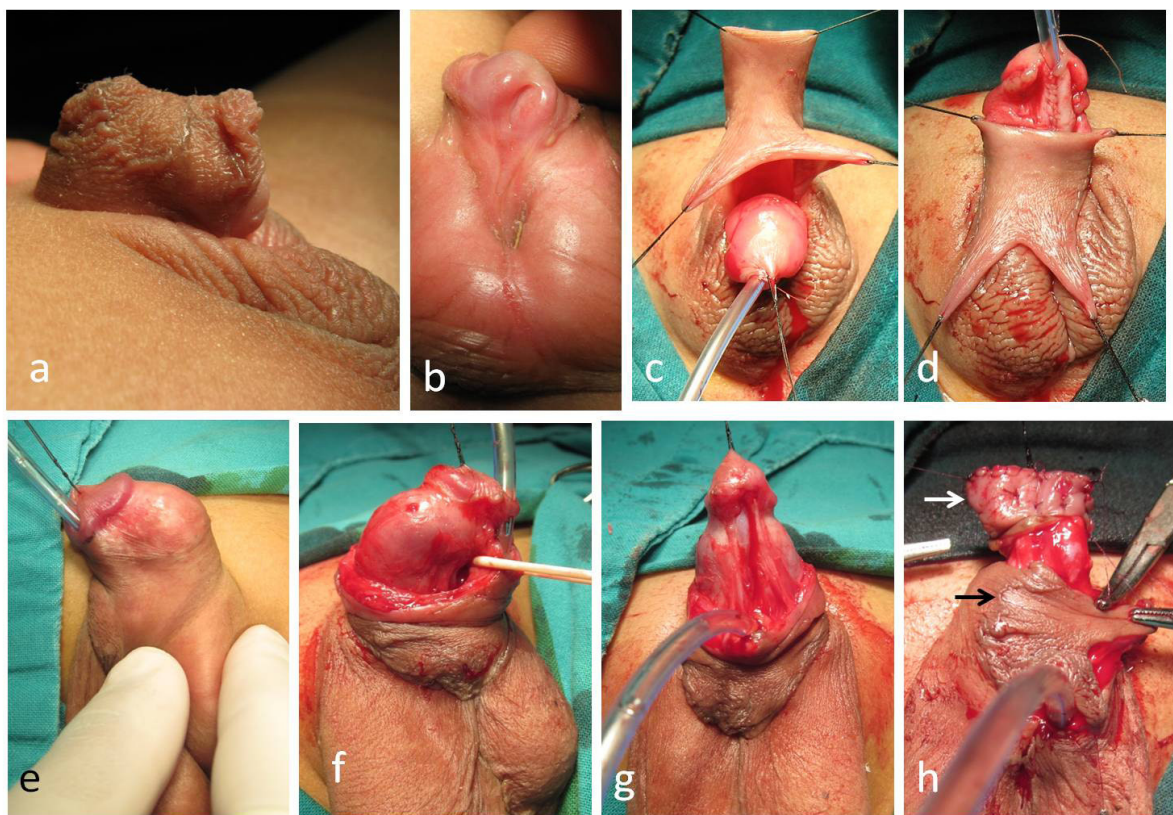
Covering the urethroplasty by a second ‘water-proofing’ layer is a common practice to decrease the rate of complications. We use dartos flaps for both distal and proximal repairs. With distal hypospadias, ventral skin deficiency is usually mild; a complete dorsal dartos flap is dissected and transferred ventrally via button-holing to cover the urethroplasty. In presence of penile torsion, the dorsal dartos flap is rotated from the opposite side to help in correction of existing penile rotation<sup>[11]</sup>. On the contrary, proximal hypospadias is always associated with significant ventral skin deficiency. To decrease postoperative skin complications, we apply a modification by splitting the dorsal prepuce into two halves (Byars flaps): one half supplies dartos for covering the urethroplasty, and the other half is spared to reconstruct the ventral penile skin (Fig. 4b and d)<sup>[12]</sup>. For a long urethroplasty, another dartos flap is dissected from the nearby scrotum to cover proximal urethroplasty (Fig. 4c and d)



**Fig. 4:** Covering a long tubularized incised plate (TIP) urethroplasty by dartos flaps in a 15-month-old boy with penoscrotal hypospadias. (a) Preoperative appearance. (b) Right Byars flap supplying dartos (white arrow) for covering TIP urethroplasty, whereas the left Byars flap (black arrow) is spared for reconstructing ventral penile skin. (c) Another dartos flap is dissected from the scrotum (\*) to cover proximal urethroplasty. (d) Note: the skin of the right flap (white arrow) has doubtful viability and will be excised (dashed line), in contrast to the reliable vascularity of the left Byars flap (black arrow) that will be rotated to cover the penile ventrum. (e, f) The patient presented 2 years later with urethrocutaneous fistula (dashed arrow). (g) Assessment of neourethra by endoscopy at time of repair of fistula (dashed arrow). (h) After excision of fistula (dashed arrow) and closure of urethra.

Occasionally, a special configuration of the prepuce and dorsal penile skin (preputial cape, Fig. 5a) can be suitable for button-holing of the dorsal skin,

which represents another way to cover the suture line of the urethroplasty and reconstruct the ventral skin (Fig. 5c and d)<sup>[13]</sup>.



**Fig. 5:** Recurrence of penile chordee after dorsal plication of the tunica albuginea and tubularized incised plate (TIP) urethroplasty. Upper row (a–d) demonstrates the primary operation (TIP urethroplasty) for a case of scrotal hypospadias at the age of 8 months: (a) crooked prepuce; (b) scrotal meatus; (c, d) button-holing of the dorsal skin (preputial cape technique) for reconstructing the ventral penile skin while covering the suture line of the TIP urethroplasty. Lower row (e–h): same patient presenting 7 years later with persistence of chordee (e); (f, g) degloving and transection of the urethra at the level of the coronal sulcus to straighten the penis with recession of the urinary meatus backward to penoscrotal position; (h) the glans is splayed open and grafted (white arrow), whereas skin flaps are used to cover the penile ventrum (black arrow), representing the first step of a staged repair.

The glanuloplasty is a last and may be the most delicate step (especially challenging with a small glans). Glanular wings are carefully prepared with adequate thickness and mobility to be easily rotated and closed in the midline without tension over the urethra. Glanular closure is preferably achieved by 2–3 subcuticular (6-0) polyglactin stitches. Usually, we do not apply the 5- and 7-o'clock stitches used to fix the meatus to the tip of the glans. According to the size of the glans, a transurethral (6–8 Fr) Nelaton catheter is left in place and fixed to the glans stay suture to drain the urinary bladder for 7 days, postoperatively. The phallus is dressed and sandwiched against the anterior abdominal wall. Unless soaked, the dressing is left to be removed with the catheter after 1 week. We believe the real value of the dressing is to apply some compression and immobilization for the penis in the early postoperative period, which can help to decrease edema and pain.

Further follow-up after 1 month, 6 months, and then yearly till puberty is recommended (especially with proximal hypospadias).

## RESULTS

We retrieved data of 193 patients with different degrees of hypospadias who underwent a primary TIP urethroplasty by the author during the 10-year period of the study. Almost all cases were uncircumcised (except two cases with distal hypospadias). All cases in the study completed their early postoperative follow-up (at 1 and 4 weeks). Approximately 40% of cases completed more than 1-year follow-up (ranging from 1–7 years; mean=2.3 years; SD=1.3). Rate of reoperation was 21.7% (20 cases for fistula, five recurrences of chordee, one meatal stenosis, and 16 skin refashioning and correction of penoscrotal transposition). All cases who returned for reoperation underwent urethral calibration under anesthesia±cystoscopy. For the rest of cases, urethral calibration was not routine in the follow-up unless there were obstructive symptoms; assessments of postvoiding residual urine volume by ultrasound, urethrograms, and flow-metry were ordered in selected cases. Table 1 summarizes the encountered complications in relation to the different degrees of hypospadias included in the study.

**Table 1:** Rate of postoperative complications following TIP repair among cases with different degrees of hypospadias

Type	No.	Fistula	Glanular dehiscence	Chordee	Meatal stenosis	Urethral stricture	Penile concealment
Distal penile	82	8 cases (9.8%)	----	----	----	----	2 cases (2.4%)
Mid penile	39	4 cases (10.3%)	4 cases	----	----	----	2 cases (5%)
Peno-scrotal	58	8 cases (13.8%)	3 cases	5 cases	3 cases	1 case	12 cases (12%)
Scrotal	14	----	1 case	1 case	----	----	9 cases (64%)
Total	193	20 cases (10.4%)	8 cases (4.1%)	6 cases (3.1%)	3 cases (1.6%)	1 case (0.5%)	25 cases (13%)

### Urethrocutaneous fistula

Overall, 20 (10.4%) cases presented with urethrocutaneous fistula following TIP urethroplasty (Fig. 4). The fistula rate was relatively higher following the repair of penoscrotal hypospadias (13.8%). The site of fistula was variable. A very distal submeatal glanular fistula was sometimes encountered following the repair of distal and mid-penile hypospadias, which was managed by cutting the skin bridge between the neomeatus and the fistula creating a single opening. More commonly, the fistula was more proximal in position (coronal or penile shaft, Fig. 4e), which was managed by excision of the fistulous tract and urethral closure supported by local dartos flap coverage with a success rate of 100%. At the beginning of the operation, urethral calibration±cystoscopy was important to exclude urethral strictures (Fig. 4g).

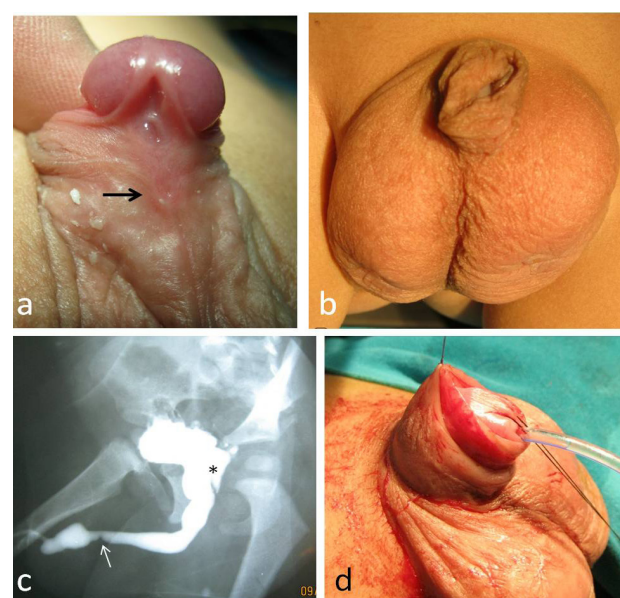
### Persistence of chordee

We had six cases of persistent chordee following TIP repair of proximal hypospadias (Fig. 5). Parents were advised to notice their children in the morning (for morning erections) and during micturition (some took photographs for the erected penis). Two cases were managed by repeating dorsal plication of the tunica albuginea; another three underwent transection of the neourethra and skin/buccal mucosal grafting of the penile ventrum (as a first step of a staged repair, Fig. 5); whereas the last case is still being followed-up.

### Meatal stenosis and urethral strictures

One case presented with recurrent attacks of epididymitis during the follow-up (Fig. 6). A urethrogram was ordered that showed urethral stricture (at the original site of the hypospadiac meatus), in addition to narrowing of the neomeatus (Fig. 6c). This case responded well to dilatation, in addition to refashioning of excess penile skin that was thought to be a possible source of ascending infection (Fig. 6b and d). Another two cases presented with a narrow urinary stream; examination revealed narrowing

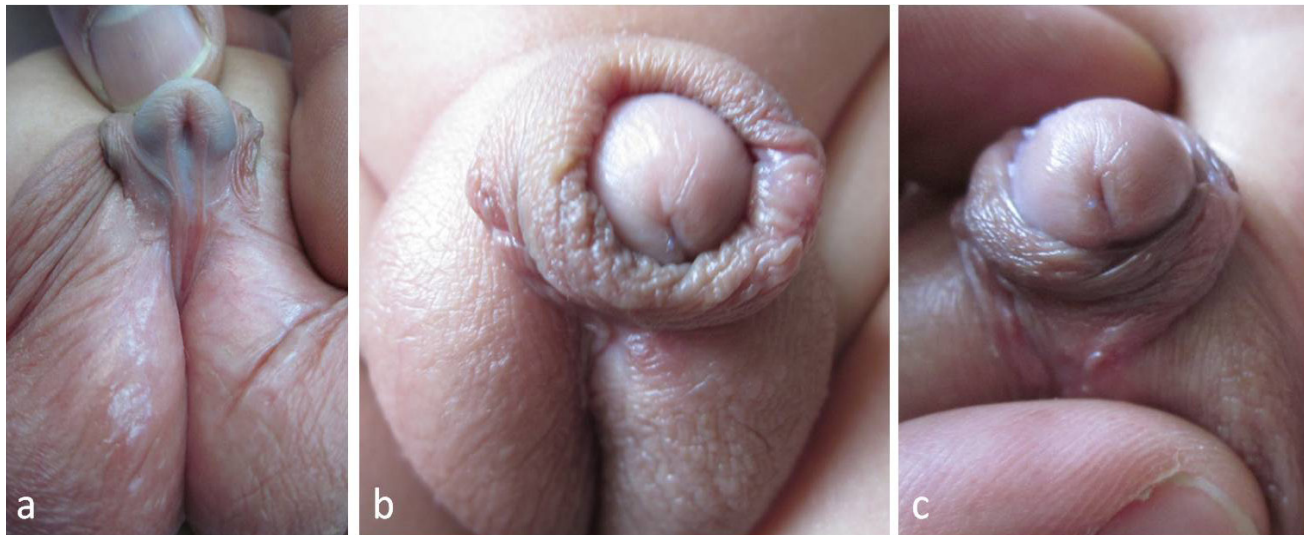
of the neomeatus. One responded to dilatation, whereas the other was managed by ventral meatotomy.



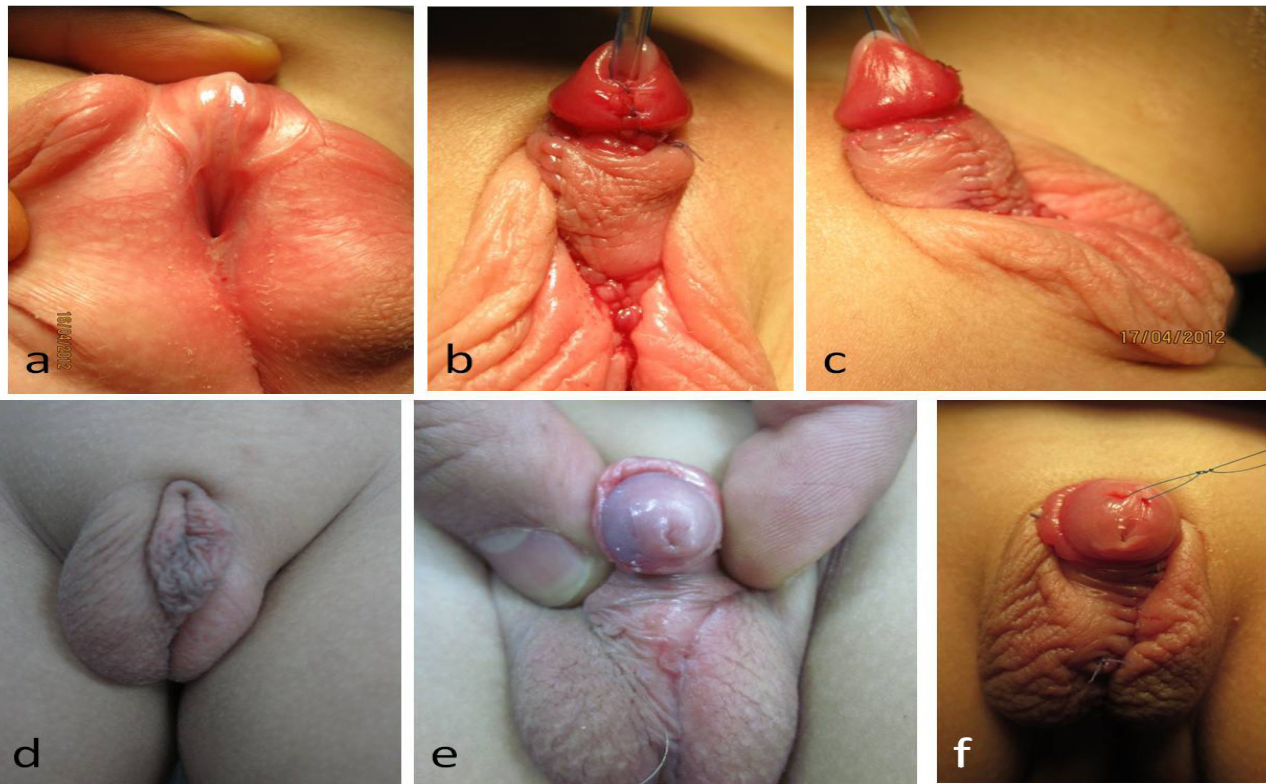
**Fig. 6:** (a) A 13-month-old boy with penoscrotal hypospadias (black arrow) underwent tubularized incised plate urethroplasty. (b) The patient presented 2 years later with recurrent attacks of epididymitis, and penile concealment. (c) Voiding urethrogram was ordered showing urethral stricture at the original site of the hypospadiac meatus (white arrow), note the prostatic utricle (\*) filled with contrast; (d) the patient was managed by urethral dilatation and refashioning of excess penile skin.

### Buried penis

This was a common complain following the repair of scrotal hypospadias (64%) owing to small size of the phallus and presence of penoscrotal transposition. The degree of penile concealment varied from partial (Fig. 7) to complete concealment (Fig. 8). Redosurgery was needed for a group of these patients to remove excess ventral skin, create penoscrotal angle on the ventral side, and correct penoscrotal transposition.



**Fig. 7:** (a) A 7-month-old boy with scrotal hypospadias underwent tubularized incised plate urethroplasty. (b, c) Follow-up 1 year later showing partial concealment. Note the vertical neomeatus.



**Fig. 8:** Upper row (a–c): A 7-month-old boy with scrotal hypospadias (small-sized phallus) underwent tubularized incised plate urethroplasty with modified Byars flaps to cover the urethroplasty and reconstruct ventral skin. Lower row (d–f): 2 years later, the same patient presenting with penile concealment (buried penis), which was managed by skin refashioning (removal of excessive ventral skin redundancy).

## DISCUSSION

Since its introduction in 1994, TIP urethroplasty has rapidly become the most popular technique used for the repair of distal hypospadias worldwide<sup>[7]</sup>. However, applying the technique in proximal hypospadias did not gain similar popularity. The main obstacle with proximal hypospadias is the presence of a short urethral plate when it must be transected to straighten the curved penis<sup>[6]</sup>. Baskin supported preservation of the urethral plate being rarely the cause of penile curvature<sup>[14,15]</sup>. Dorsal penile plication and urethral plate elevation (mobilization) are two maneuvers that have been described to correct chordee while preserving the urethral plate for urethroplasty<sup>[6]</sup>; however, recurrence of chordee remains a major concern that seems to be under-reported in the literature<sup>[2,16,17]</sup>. Moreover, exaggeration of penile chordee may be expected as the child goes into puberty<sup>[3,7,10]</sup>. Therefore, the threshold for sacrificing the urethral plate has been lowered in most recent reports<sup>[2,18]</sup>; only mild ventral curvature (<30°) would be suitable for techniques that preserve the urethral plate<sup>[3]</sup>. Similarly, during the first half of our study period, the rate of TIP urethroplasty (urethral plate preservation) in penoscrotal and scrotal hypospadias was relatively high (80%), which dropped to 45% in the second half of the study.

Stricture of the neourethra is another major concern following TIP urethroplasty especially with proximal hypospadias<sup>[7]</sup>. In proximal hypospadias, the plate is usually narrower and the urethroplasty is longer making it more liable for complications. Reports have shown TIP urethroplasty to be associated with lower 'Qmax' (in flow metric studies) compared with other techniques<sup>[3]</sup>; however, the difference was nonsignificant and transient (improved on long-term follow-up)<sup>[19]</sup>. It is of utmost importance to make sure that patients with repaired hypospadias do not have functional urinary problems, as they usually do not have these problems before surgical repair<sup>[20]</sup>. In our practice, urethral calibration was not routine in the follow-up unless there were obstructive symptoms. Observing the child during micturition and measuring residual urine volume by ultrasound were very helpful and reassuring for both parents and doctors; urethrograms, cystoscopy, and flow-metry can be of value in selected cases. Cases that return for reoperation (fistula, chordee, skin refashioning) represent an excellent opportunity to evaluate the neourethra under anesthesia (endoscopy/calibration)<sup>[10]</sup>; this group represented 21% of our cases. In our practice, we report a very low incidence of urethral strictures (0.5%) following TIP urethroplasty (only one case that showed good response to dilatation). We had another two cases of meatal stenosis, and one of them required ventral meatotomy.

Urethrocutaneous fistula is a famous complication following hypospadias surgery. In absence of strictures, the management is usually straightforward; the main drawback being the need for a reoperation. The incidence

of urethrocutaneous fistula has been significantly reduced after spreading the concept of covering the urethroplasty by a second 'water-proofing' layer<sup>[21]</sup>. With distal hypospadias, covering the urethroplasty by a dorsal dartos flap is most popular, whereas with proximal hypospadias, the tunica vaginalis flap is another attractive alternative having the advantage of sparing intact vascularity of the dorsal skin to be used for coverage of the ventral shaft<sup>[22,23]</sup>. We have applied some modifications to facilitate covering the urethroplasty in proximal hypospadias by dartos flaps as well<sup>[12,13]</sup>. By these modifications, we managed to minimize skin complications and avoid unnecessary dissection around the testis and spermatic cord for preparing the tunica vaginalis flap.

Other factors have been discussed in the literature concerning the suture material, suturing technique, types of needles, urinary diversion, and ways of dressing<sup>[18]</sup>. Although these factors may still have some effect, yet its effect on the outcome seems to be limited. We used 6-0 polyglactin, single-layer, full-thickness (through and through), continuous suturing for the urethroplasty; we drain the bladder by transurethral nelaton catheter for 7 days; and we splint the phallus in a dressing against the abdominal wall. Our results are 'more or less' comparable with other reports in the literature regarding the rate of complications following TIP repair for both distal and proximal forms of hypospadias<sup>[2,5,6,8]</sup>.

In this case series, the high incidence of penile concealment following TIP repair for scrotal hypospadias seems to be a peculiar but expected finding. This may be related to applying some skin flap modifications resulting in exaggeration of ventral skin redundancy, in addition to other inherit factors (small size of the phallus and penoscrotal transposition). Some authors recommend always shifting to staged repair rather than a TIP urethroplasty in cases with small hypospadiac phallus<sup>[3]</sup>. We believe the existence of considerable chordee with hypospadias is a clear indication for a staged repair (or other alternative techniques) to increase the length of an already shortened urethra<sup>[3]</sup>. However, for a small phallus without considerable chordee, the justification for sacrificing the urethral plate is not that clear. Unless indicated, adding extra length to the urethra is not free of possible adverse effects: increasing resistance to urine flow, liability to strictures, and diverticulae<sup>[7,16]</sup>. Long-term follow-up of these children as they go into puberty would be of utmost importance to be able to judge on the 'final' outcome and recognize the most suitable technique<sup>[7]</sup>.

The study has the usual limitations of retrospective studies. We did not apply any of the described scoring systems to assess the phenotypic severity of hypospadias; instead, the author carefully documented his practice over the years of the study utilizing digital photography. This has been found to be very useful, especially when correlating the outcome to saved photographs of the primary operation<sup>[24]</sup>. This study represents a single-surgeon experience which may be beneficial from one aspect, namely, unification

of the surgical technique. Meanwhile, evaluation of the outcome was carried out by the operating surgeon when bias cannot be completely excluded. However, TIP urethroplasty is a well-established surgical procedure known for its simplicity and reproducibility<sup>[6]</sup>. Our main aim was to identify the rate of complications of a such common procedure over a reasonable period of follow-up. Moreover, we tried to clarify the main limitations of the technique in repairing the more severe degrees of hypospadias when the indication of a TIP urethroplasty remains somehow controversial<sup>[2,3]</sup>.

## CONCLUSION

TIP urethroplasty is a versatile technique that can be used for the repair of different degrees of hypospadias with low rate of complications. The main limitation is the presence of considerable chordee (moderate or severe) when urethral plate preservation and dorsal penile plication might be a suboptimal way of management that is liable for recurrence of the ventral curvature.

## CONFLICT OF INTEREST

There are no conflicts of interest.

## REFERENCES

1. Winship BB, Rushton HG, Pohl HG. In pursuit of the perfect penis: Hypospadias repair outcomes. *J Pediatr Urol* 2017; 13: 285–288.
2. Pippi Salle JL, Sayed S, Salle A, Bagli D, Farhat W, Koyle M, Lorenzo AJ. Proximal hypospadias: a persistent challenge. Single institution outcome analysis of three surgical techniques over a 10-year period. *J Pediatr Urol* 2016; 12: 28.e1–28.e7.
3. Castagnetti M, El-Ghoneimi A. Surgical management of primary severe hypospadias in children: systematic 20-year review. *J Urol* 2010; 184: 1469–1475.
4. Snodgrass W. Tubularized incised plate urethroplasty for distal hypospadias. *J Urol* 1994; 151: 464–465.
5. Snodgrass W, Yucel S. Tubularized incised plate for mid shaft and proximal hypospadias repair. *J Urol* 2007; 177: 698–702.
6. Bhat A. Extended urethral mobilization in incised plate urethroplasty for severe hypospadias: a variation in technique to improve chordee correction. *J Urol* 2007; 187: 1031–1035.
7. Gong EM, Cheng EY. Current challenges with proximal hypospadias: we have a long way to go. *J Pediatr Urol* 2017; 13:457–467.
8. Steven L, Cherian A, Yankovic F, Mathur A, Kulkarni M, Cuckow P. Current practice in paediatric hypospadias surgery: a specialist survey. *J Pediatr Urol* 2013; 9: 1126–1130.
9. Springer A, Krois W, Horcher E. Trends in hypospadias surgery: results of a worldwide survey. *Eur Urol* 2011; 60: 1184–1189.
10. Long CJ, Chu DI, Tenney RW, Morris AR, Weiss DA, Shukla AR. Intermediate-term followup of proximal hypospadias repair reveals high complication rate. *J Urol* 2017; 197: 852–858.
11. AbouZeid A, Soliman H. Penile torsion: an overlooked anomaly with distal hypospadias. *Ann Pediatr Surg* 2010; 6: 93–97.
12. AbouZeid A. Modified Byars' flaps for securing skin closure in proximal and mid-penile hypospadias. *Ther Adv Urol* 2011; 3: 251–256.
13. AbouZeid A, Safoury HS. The preputial cape: a distinct and favorable morphological variant in hypospadias. *J Plastic Reconstr Aesthet Surg* 2011; 64: e270–e272.
14. de Mattos e Silva E, Gorduza DB, Catti M, Valmalle AF, Delphine Demede D, Hameury F, *et al.* Outcome of severe hypospadias repair using three different techniques. *J Pediatr Urol* 2009; 5: 205–211.
15. Hayashi Y, Kojima Y, Nakane A, Maruyama T, Tozawa K, Kohri K. A strategy for repairing moderately severe hypospadias using onlay urethroplasty versus onlay-tube-onlay urethroplasty. *Urology* 2003; 61:1019–1022.
16. Long CJ, Canning DA. Hypospadias: are we as good as we think when we correct proximal hypospadias? *J Pediatr Urol* 2016; 12: 196.e1–196.e5.
17. Braga LH, Lorenzo AJ, Bagli DJ, Dave S, Eeg K, Farhat WA, *et al.* Ventral penile lengthening versus dorsal plication for severe ventral curvature in children with proximal hypospadias. *J Urol* 2008; 180:1743–1747.
18. Snodgrass W, Bush N. TIP hypospadias repair: a pediatric urology indicator operation. *J Pediatr Urol* 2016; 12: 11–18.
19. Hueber P, Diaz MS, Chaussy Y, Franc-Guimond J, Barrieras D, Houle A. Long-term functional outcomes after penoscrotal hypospadias repair: a retrospective comparative study of proximal TIP, Onlay, and Duckett. *J Pediatr Urol* 2016; 12:168.e1–168.e6.



20. Harper L. Editorial comment. *J Urol* 2015; 193: 981–982; (discussion 982)
21. Retik AB, Mandell J, Bauer SB, Atala A. Meatal based hypospadias repair with the use of a dorsal subcutaneous flap to prevent urethrocutaneous fistula. *J Urol* 1994; 152: 1229–1231.
22. Snow BW. Use of tunica vaginalis to prevent fistulas in hypospadias surgery. *J Urol* 1986; 136:861–863.
23. Snodgrass W, Bush N. Tubularized incised plate proximal hypospadias repair: Continued evolution and extended applications. *J Pediatr Urol* 2011; 7:2–9.
24. Baskin L. Editorial comment. *J Urol* 2010; 184:1474–1475.